

PH-2

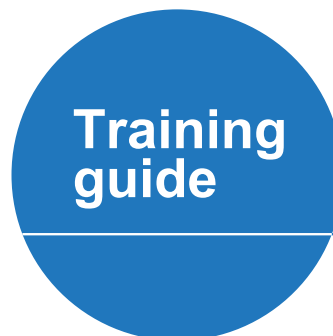Whole Body Phantom PBU-50

PH-2B

CT Whole Body Phantom PBU-60

Production supervision:
Kyoto College of Medical Science
Photography cooperation:
Kyoto College of Medical Science

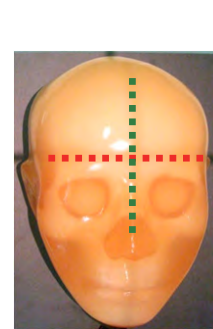
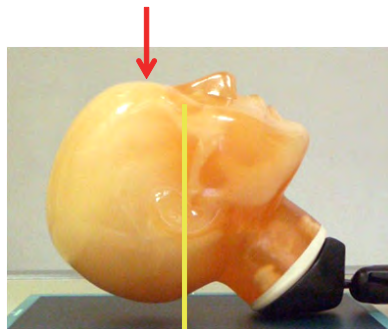


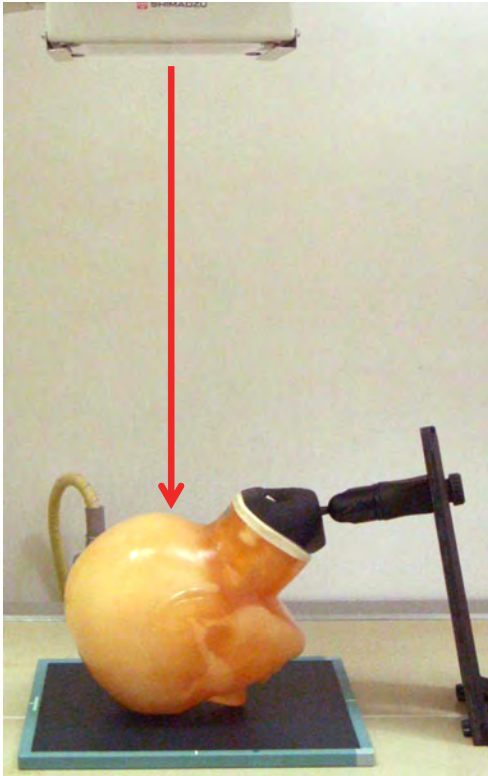
Toshifumi Kasai
Keiko Toyama



Contents

- **Point of X-ray Photography**
 - Head radiography** P.1 ~ P.5
 - Postero anterior (PA) projection of Skull
 - Lateral projection of skull
 - Townes
 - Axial projection of skull
 - Other head radiography
 - Chest radiography** P.6 ~ P. 10
 - Frontal chest radiography
 - Frontal shoulder projection
 - Frontal projection of superior and inferior ribs
 - Frontal projection of cervical spine
 - Frontal projection of thoracic spine
 - Abdomen radiography** P.11 ~ P. 15
 - Frontal projection of abdomen in supine position
 - Frontal projection of lumbar spine
 - Frontal projection of pelvis
 - Frontal projection of hip joint
 - Lauenstein projection
 - Arms radiography**P.16 ~ P. 20
 - Frontal projection of hand and finger joints
 - Lateral projection of hand and finger joints
 - Frontal projection of fingers
 - Oblique projection of fingers
 - Other arms radiography
 - Lower limbs radiography** P.21 ~ P. 24
 - Frontal projection of knee joint
 - Lateral projection of knee joint
 - Oblique projection of foot joint
 - Lateral projection of foot joint

● Point of X-ray Photography: Positioning and Direction of X-ray Radiation



* For skull AP radiography, radiate on the center of the glabella.

● Positioning

Prone position (place the face on the film area.)

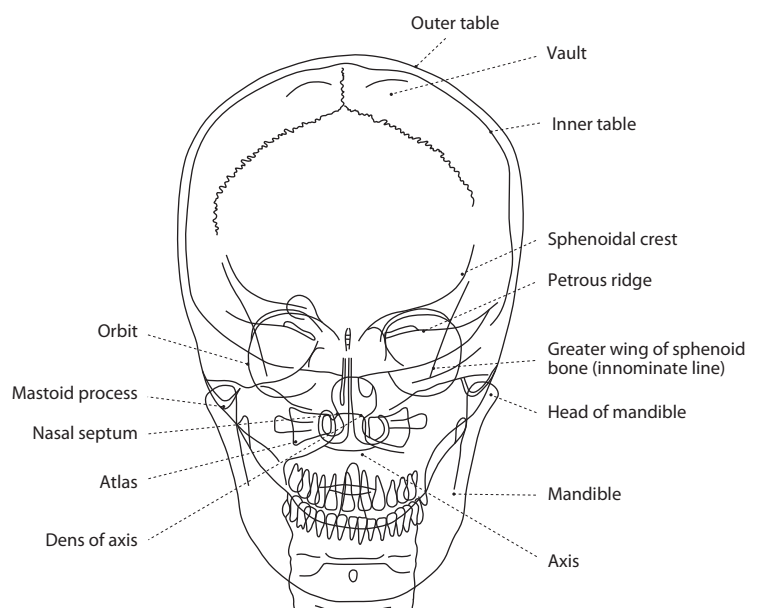
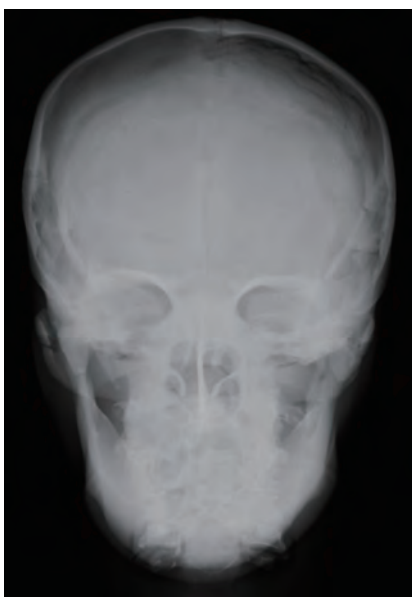● Direction of X-ray Radiation

Align the center to the external occipital protuberance. Radiate X-ray parallel to the OM line (the orbito-meatal line that is drawn from the center of orbit (outer canthus) to the external acoustic foramen).

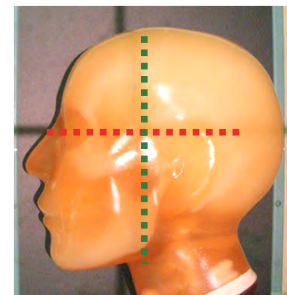



● Part of phantom used for this photography

head

● Xray image and the name of bone

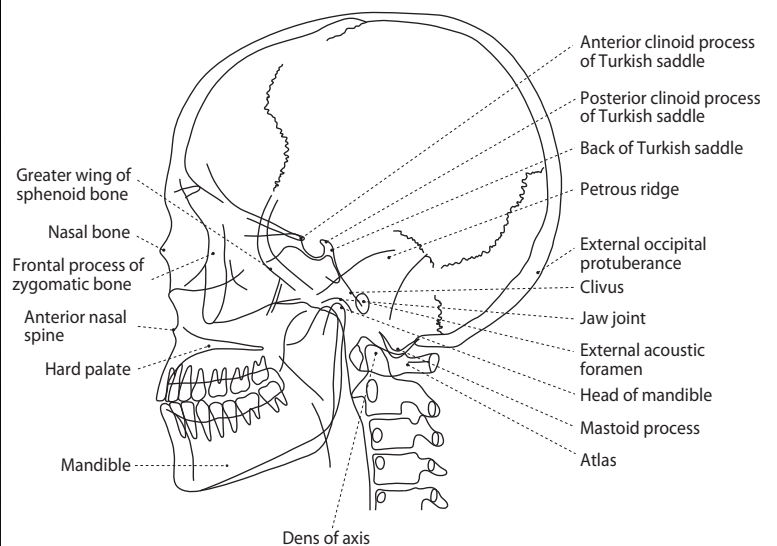
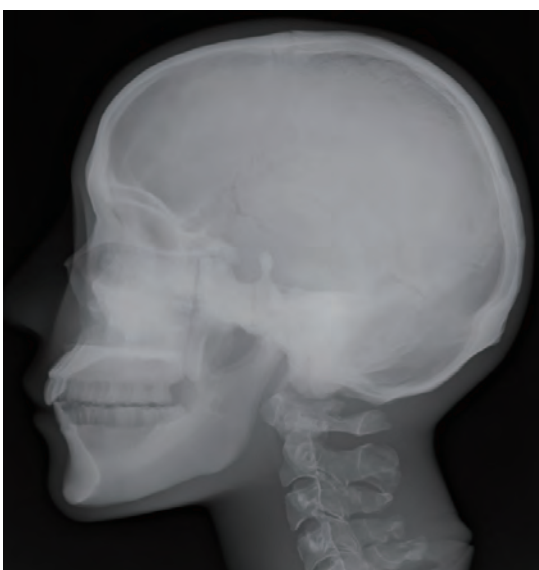

● Point of X-ray Photography: Positioning and Direction of X-ray Radiation

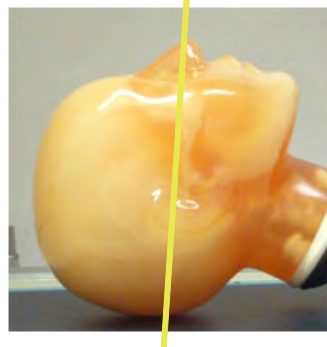
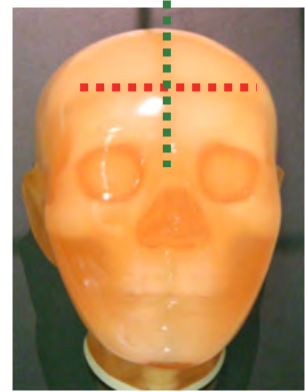




| ● Positioning | ● Direction of X-ray Radiation | ● Part of phantom used for this photography |
|---|--|---|
| Prone position (align the chest parallel to the film area and keep the facial plane perpendicular to the film.) | Align the center to the point that is shifted by 2.5cm from the external acoustic foramen and by 2.5cm to the vertex. Radiate X-ray perpendicular to the median plane (the perpendicular plane that separates the body into halves on the center of it). | head |

● Xray image and the name of bone



● Point of X-ray Photography: Positioning and Direction of X-ray Radiation



Keep the Frankfurt line 80 degrees to the film plane.

● Positioning

Supine position (place the back of the head on the film area.)

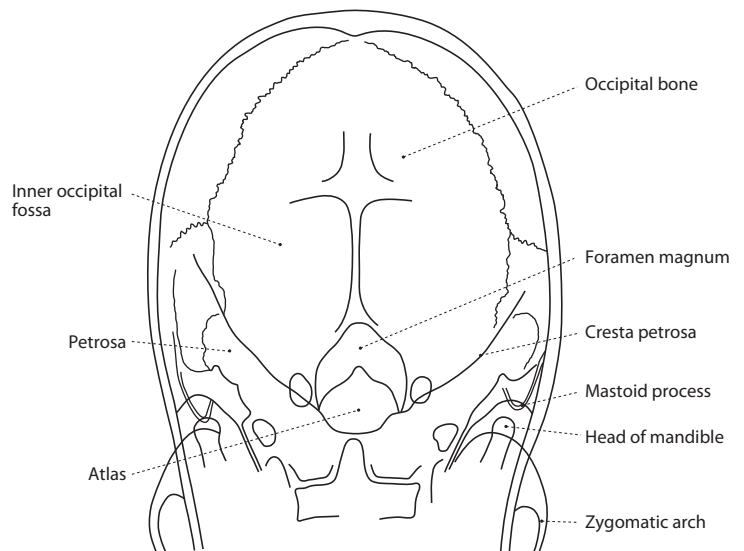
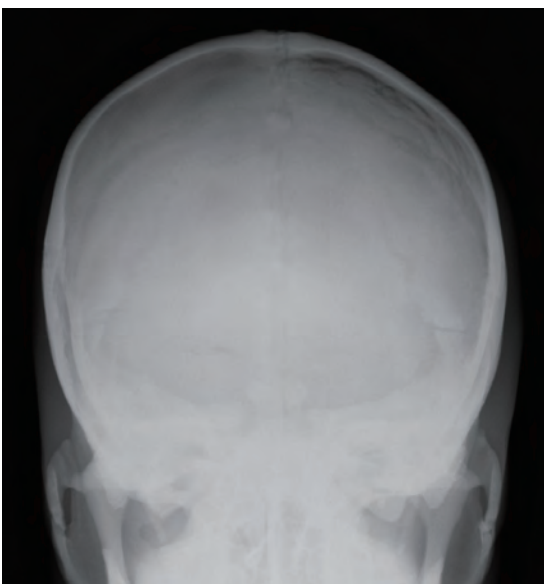
● Direction of X-ray Radiation

Align the center to the midpoint of the line connecting both the external acoustic foramina. Radiate X-ray towards the center 20 - 40 degrees from the face plane.

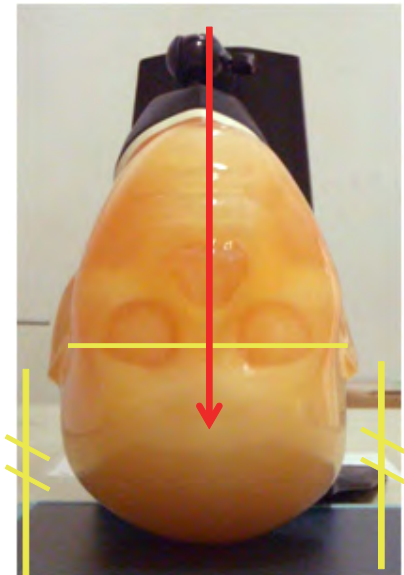
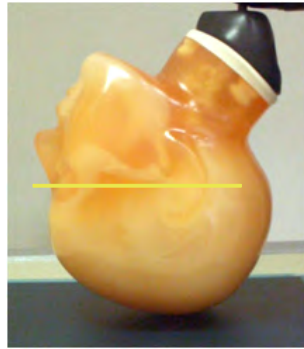
● Part of phantom used for this photography

head

● Xray image and the name of bone



● Point of X-ray Photography: Positioning and Direction of X-ray Radiation



● Positioning

Supine position (place the parietal region on the film area.)

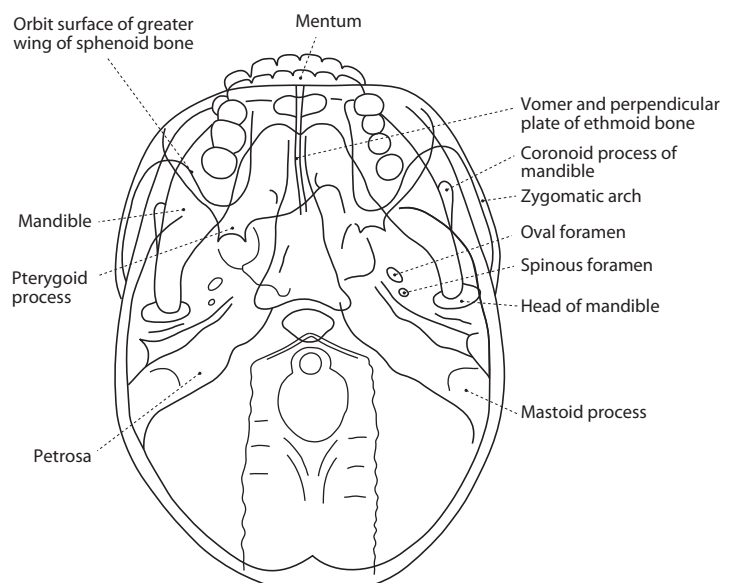
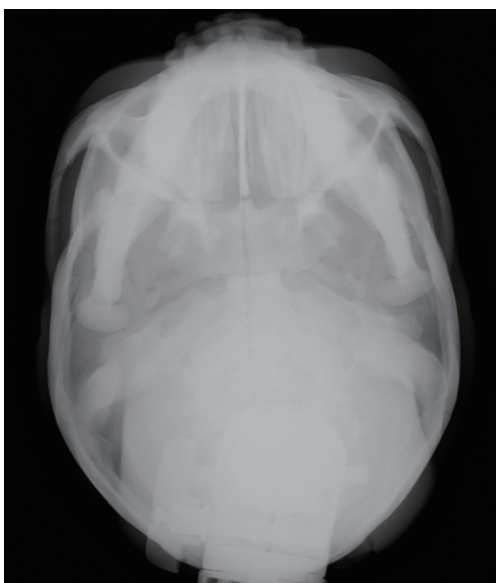
● Direction of X-ray Radiation

Align the center to a point around the intersection of the neck and the submaxillary. Radiate X-ray perpendicular to the OM line or in the direction 10 degrees inclined from the foot.


● Part of phantom used for this photography

head


● Xray image and the name of bone



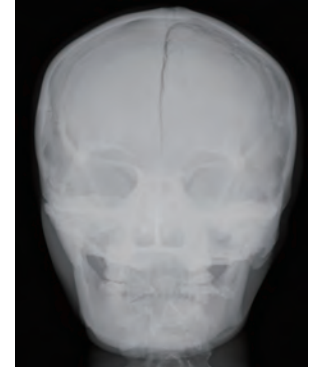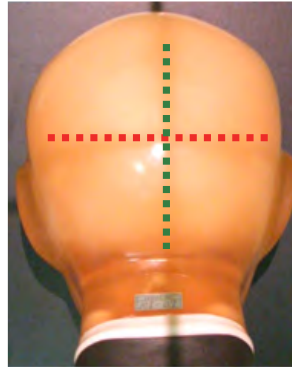
● Caldwell



Radiate X-ray to the root of nose (nasal point).

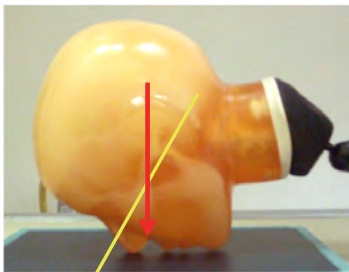


Align the OM line perpendicular to the film.

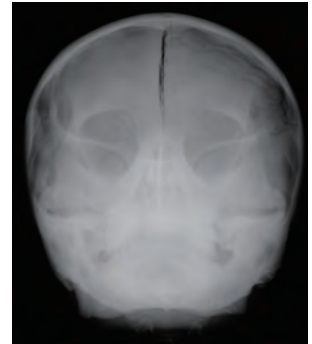

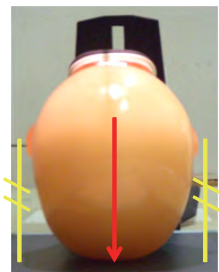


● Waters


Radiate X-ray to the lower end of the nasal cavity.



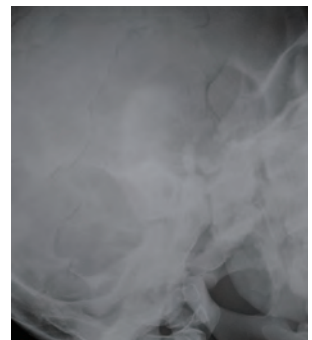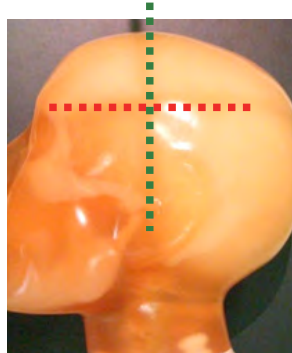
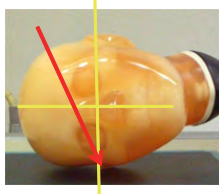
Keep the Frankfurt line 45 degrees to the film plane.



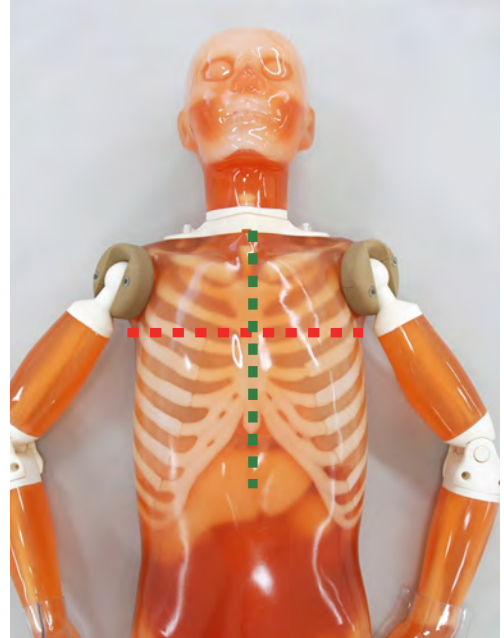

● Schuller



Radiate X-ray to the external acoustic foramen of the detector side at a 20 - 30 degrees inclination to the head from the Frankfurt line.

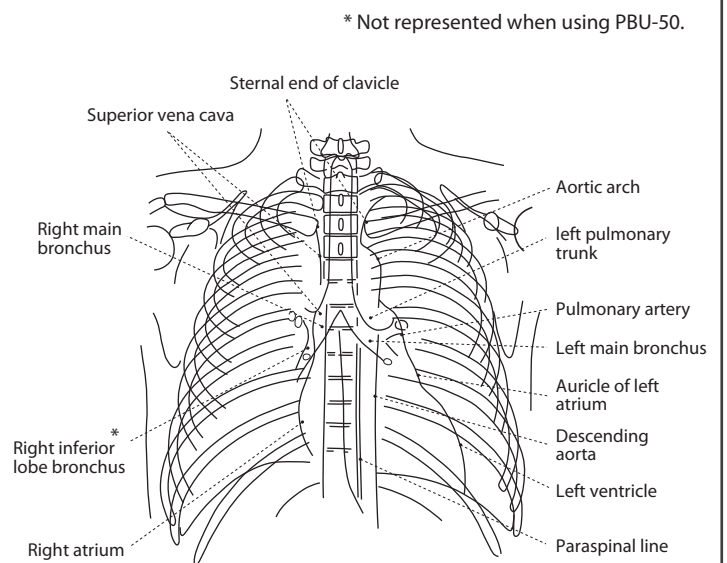
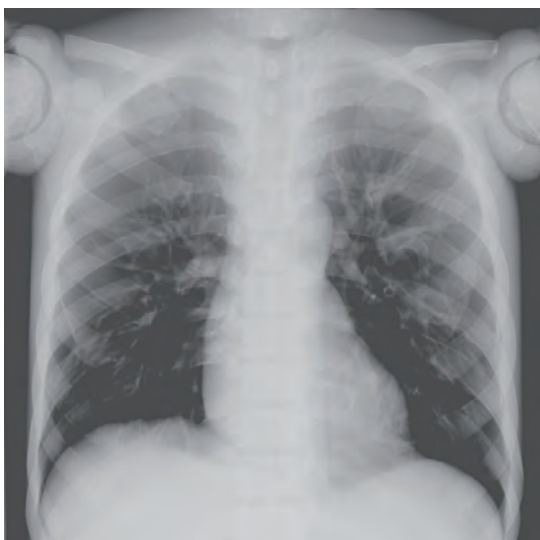

● Point of X-ray Photography: Positioning and Direction of X-ray Radiation

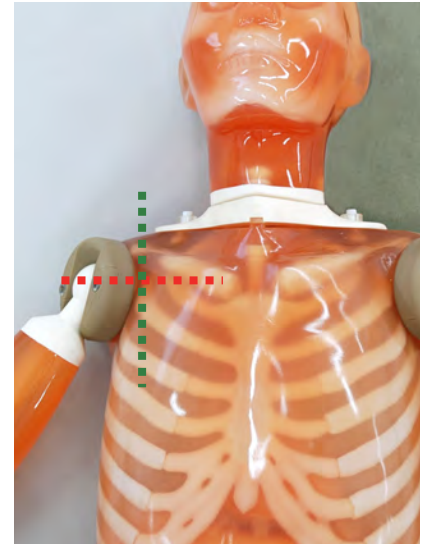
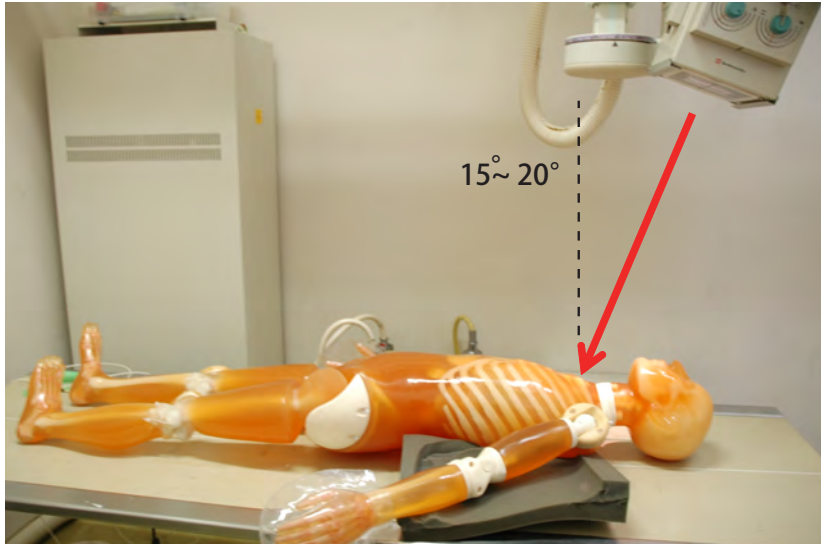


| ● Positioning | ● Direction of X-ray Radiation | ● Part of phantom used for this photography |
|-----------------|---|---|
| Supine position | Align the center to a point approximately 3cm from the center of the sternum. Radiate X-ray to the center along median plane. | trunk |

● Xray image and the name of bone

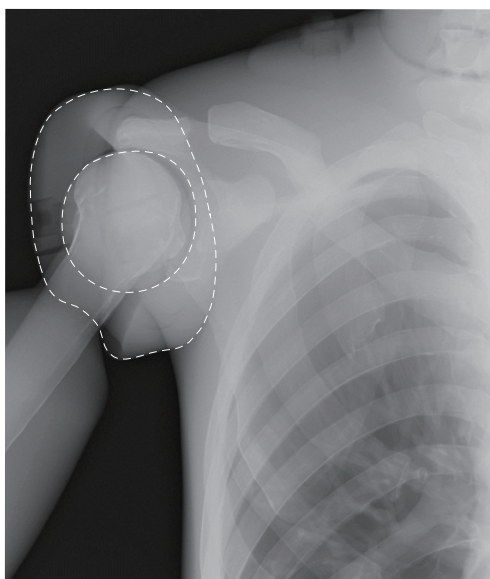


● Point of X-ray Photography: Positioning and Direction of X-ray Radiation

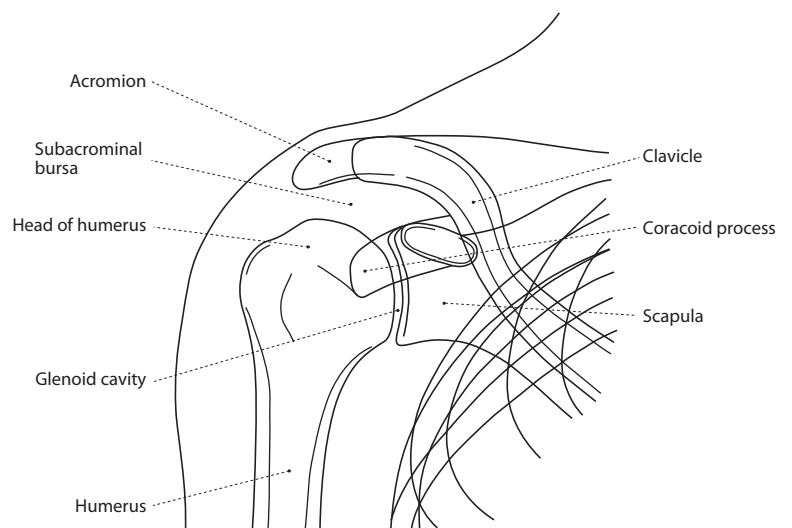


| ● Positioning | ● Direction of X-ray Radiation | ● Part of phantom used for this photography |
|---|--|---|
| Spine position (place the targeted shoulder on the film area and leave the body at an angle.) | Radiate X-ray to a point around the coracoid process at a 15 - 20 degrees inclination to the head. | trunk |

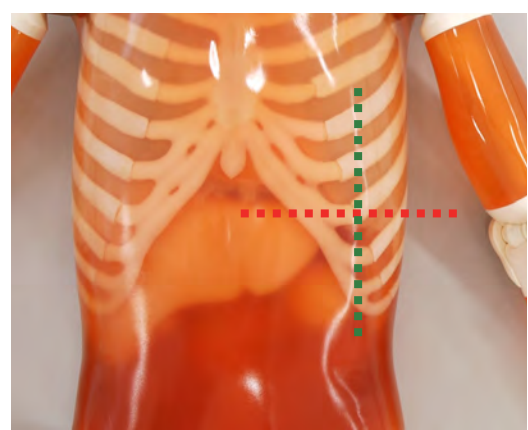
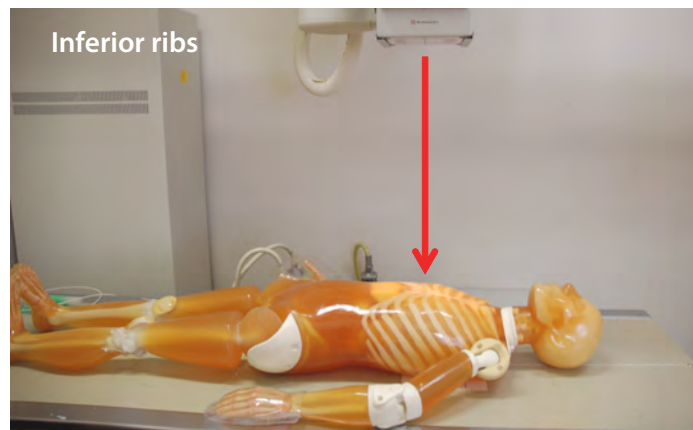
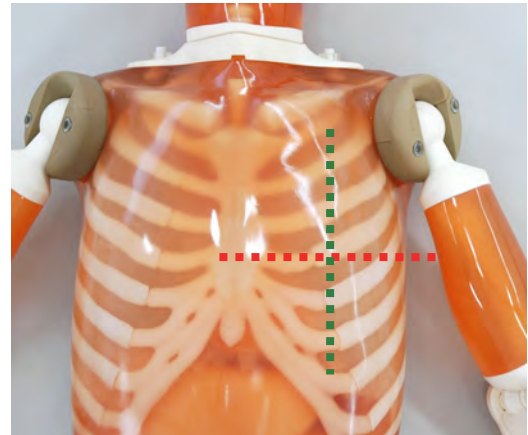
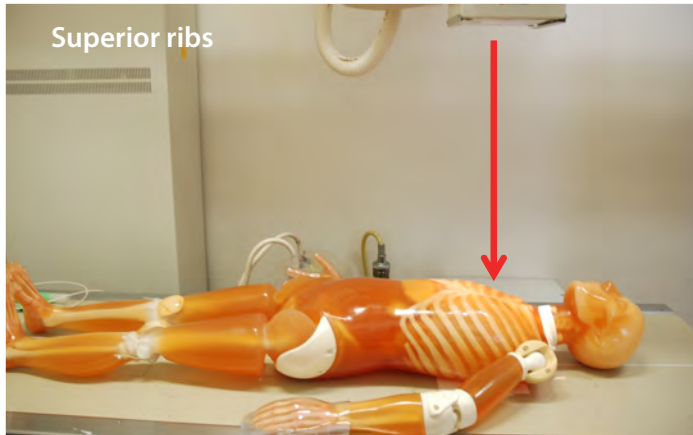
● Xray image and the name of bone



----- The connection part of the shoulder

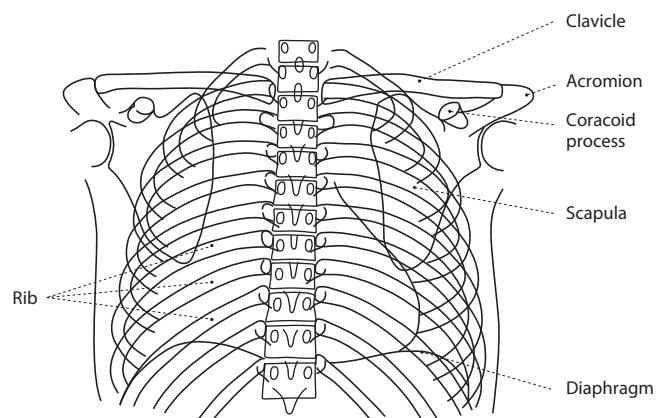
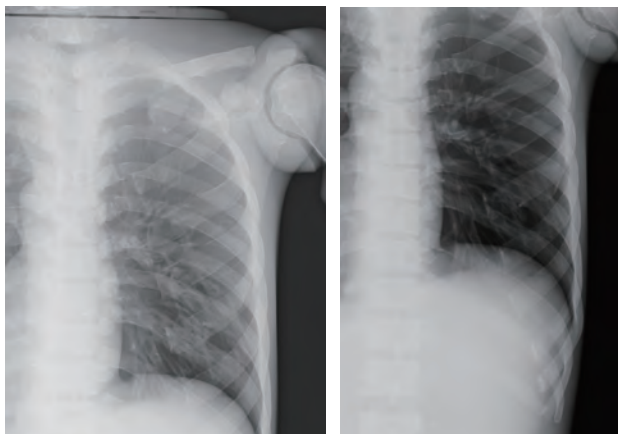


● Point of X-ray Photography: Positioning and Direction of X-ray Radiation

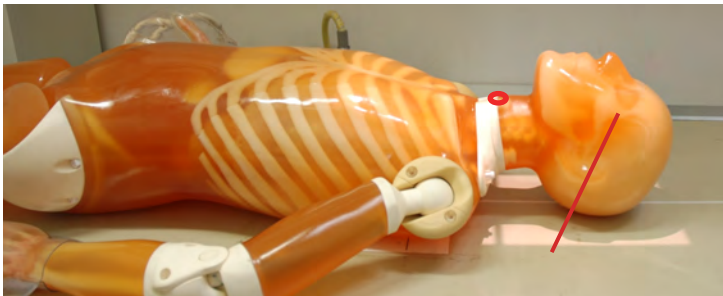
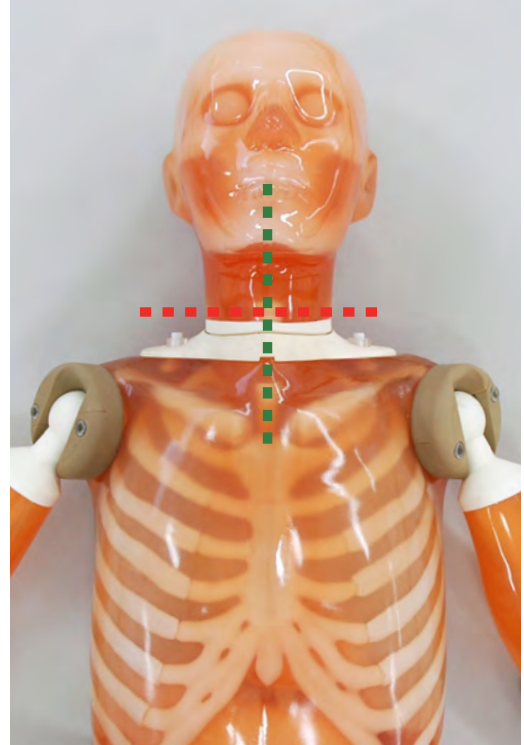
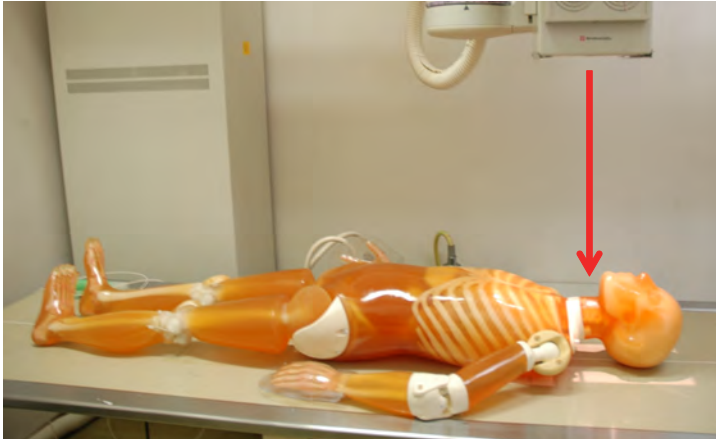

| ● Positioning | ● Direction of X-ray Radiation | ● Part of phantom used for this photography |
|-----------------|---|---|
| Supine position | Align the center to the center of the 5th or 6th rib for the superior ribs; and the center of the 8th or 9th rib for the inferior ribs. Radiate X-ray to the center in the perpendicular direction. | trunk |

● Xray image and the name of bone



● Point of X-ray Photography: Positioning and Direction of X-ray Radiation



● Positioning

Supine position (tilt the OM line 30 degrees from the perpendicular position.)

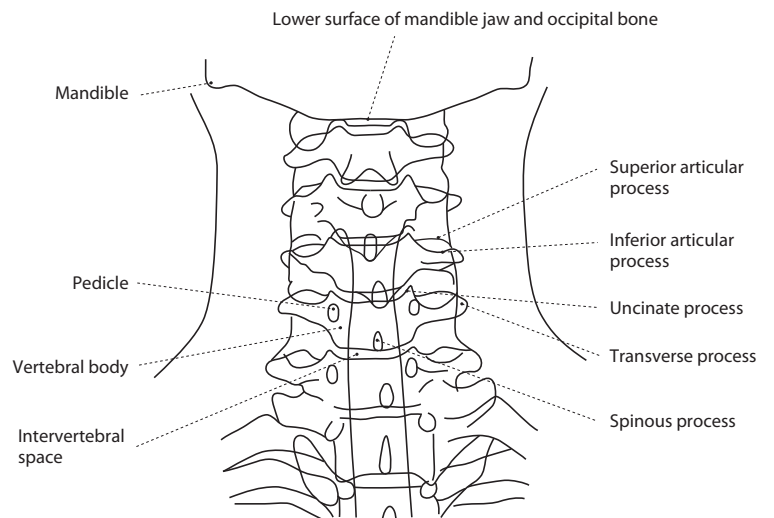
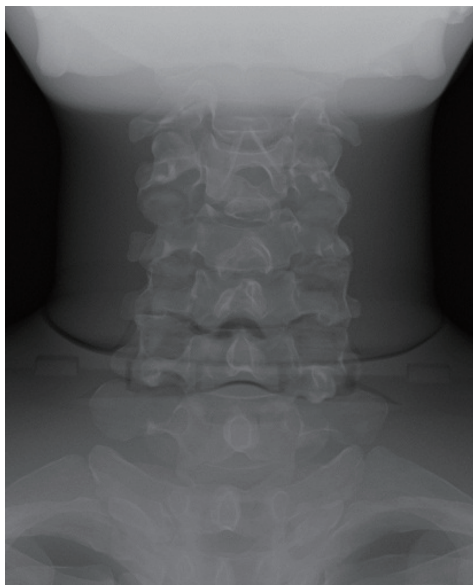
● Direction of X-ray Radiation

Align the center to a point slightly shifted to the head from the connection part along the center line of the phantom. Radiate X-ray along median plane.

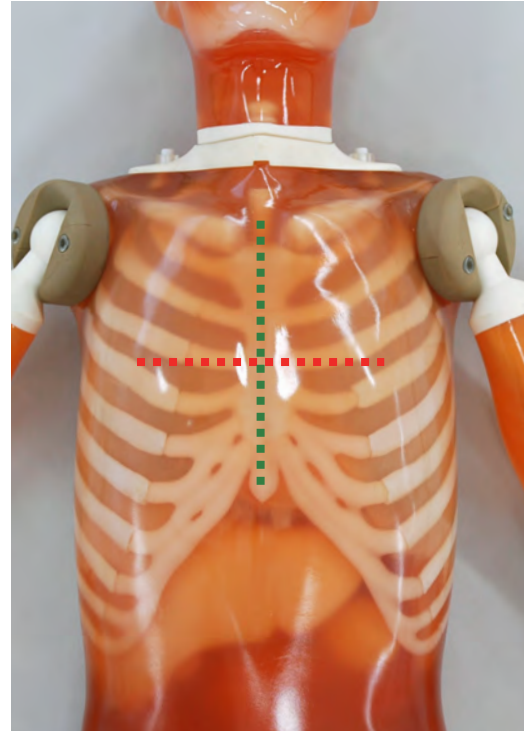
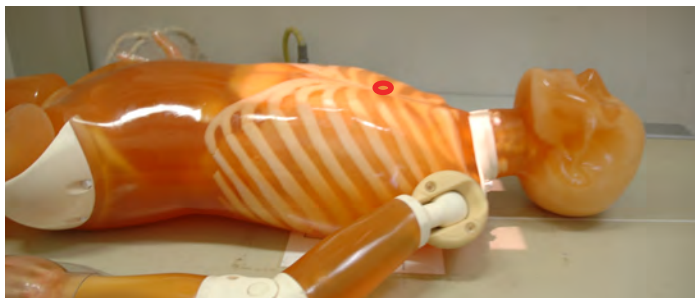
● Part of phantom used for this photography

head • trunk

● Xray image and the name of bone

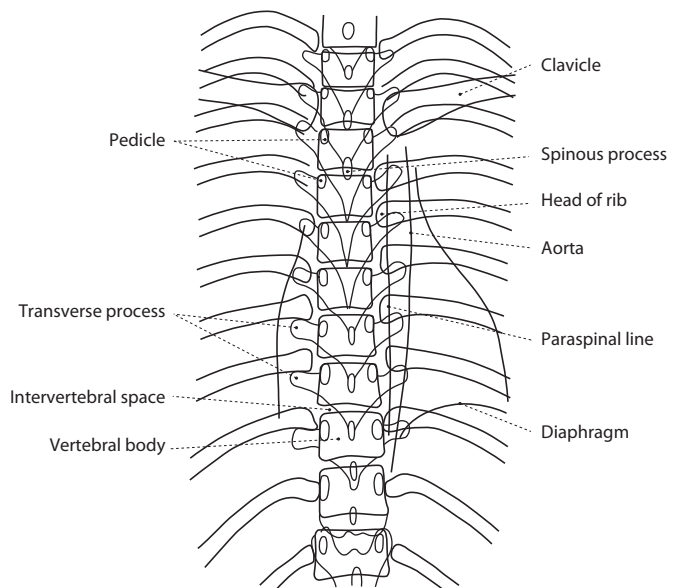
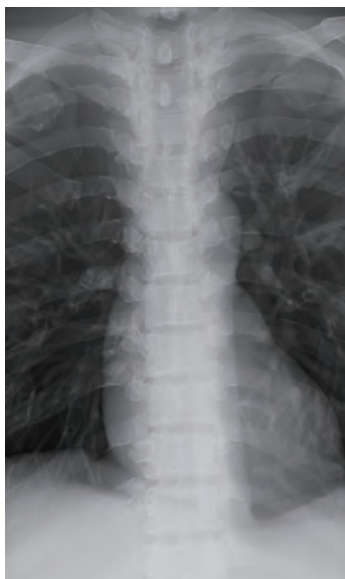


● Point of X-ray Photography: Positioning and Direction of X-ray Radiation

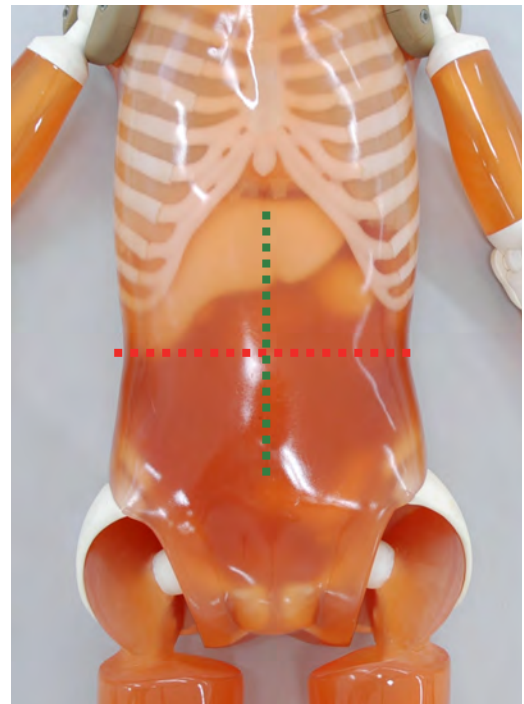
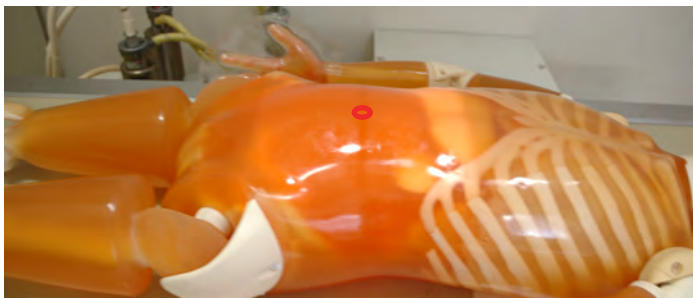


| ● Positioning | ● Direction of X-ray Radiation | ● Part of phantom used for this photography |
|-----------------|--|---|
| Supine position | Align the center to the center of the sternum. Radiate X-ray along median plane. | trunk |

● Xray image and the name of bone

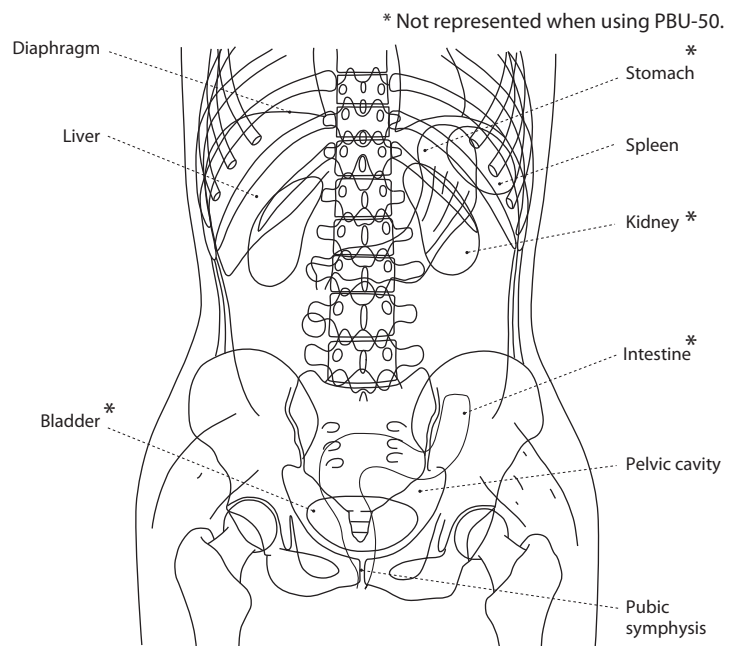
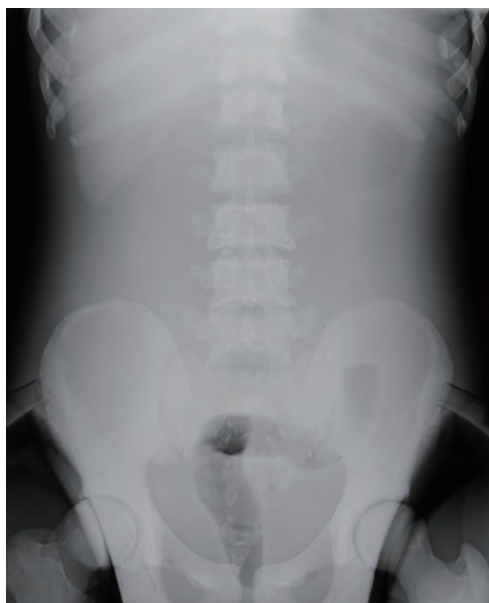

● Point of X-ray Photography: Positioning and Direction of X-ray Radiation

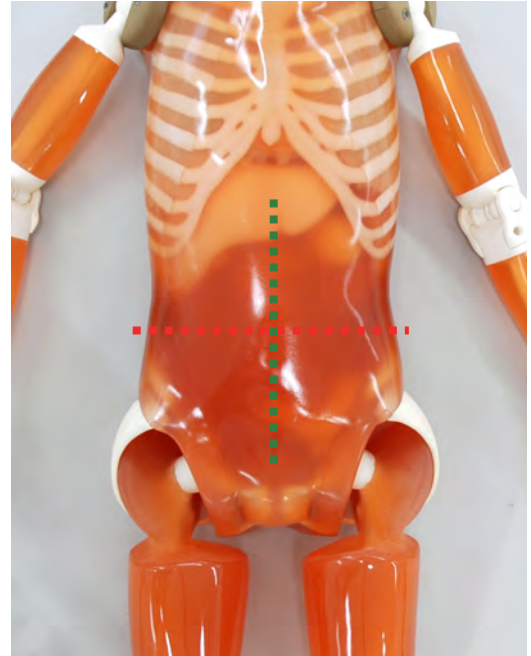
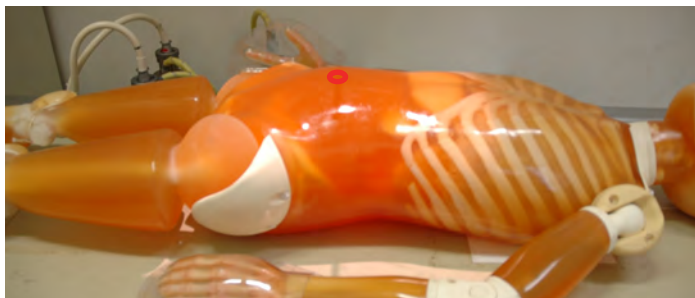


| ● Positioning | ● Direction of X-ray Radiation | ● Part of phantom used for this photography |
|-----------------|---|---|
| Supine position | Align the center to the midpoint between the line connecting the center of the Jacoby's line (which connects the iliac crests) and the xiphoid process. Radiate X-ray along median plane. | trunk • thigh |

● Xray image and the name of bone

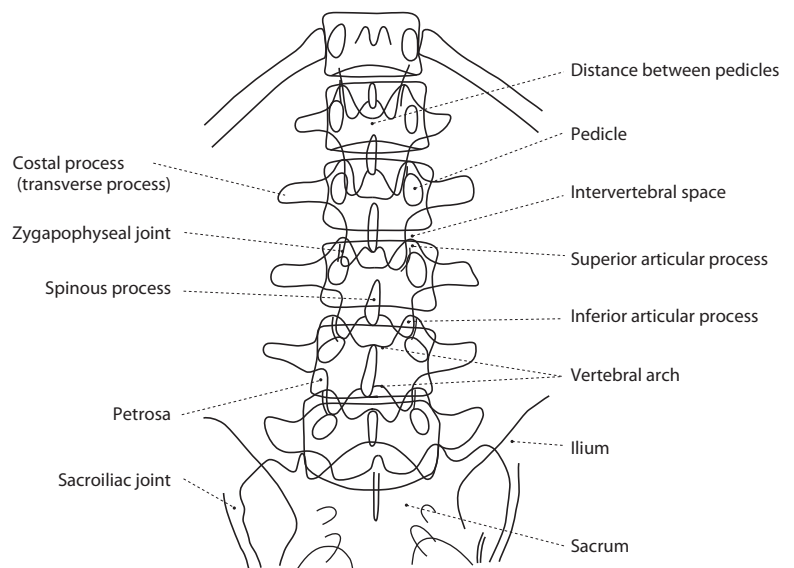
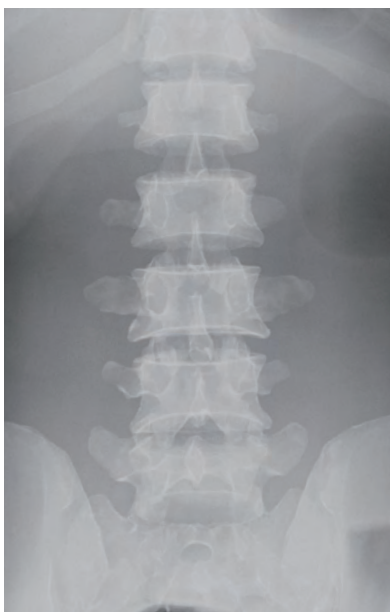

● Point of X-ray Photography: Positioning and Direction of X-ray Radiation

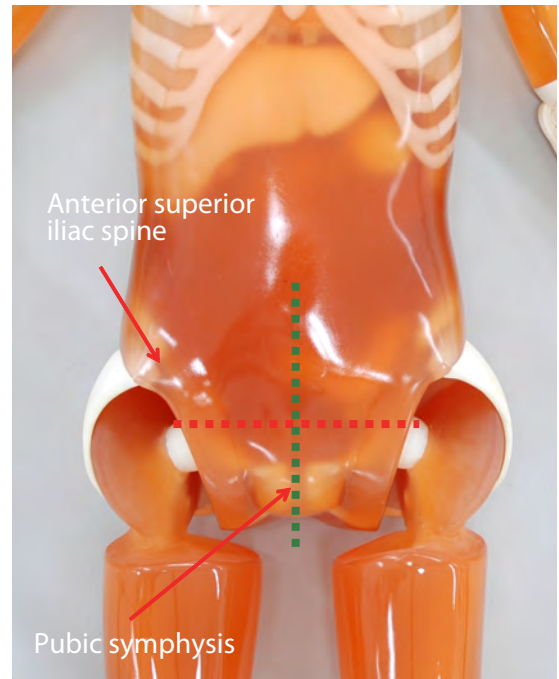
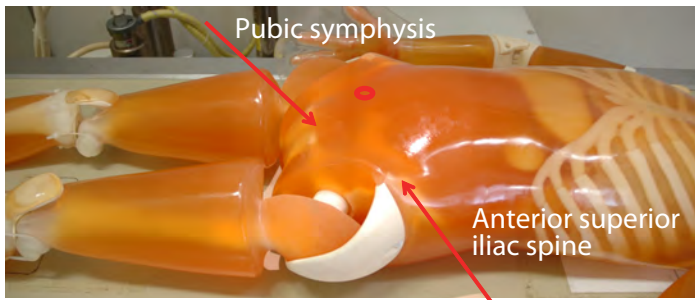



| ● Positioning | ● Direction of X-ray Radiation | ● Part of phantom used for this photography |
|-----------------|---|---|
| Supine position | Align the center to the midpoint between the line connecting the lower edges of the ribs of the both sides and the Jacoby's line. Radiate X-ray along median plane. | trunk |

● Xray image and the name of bone



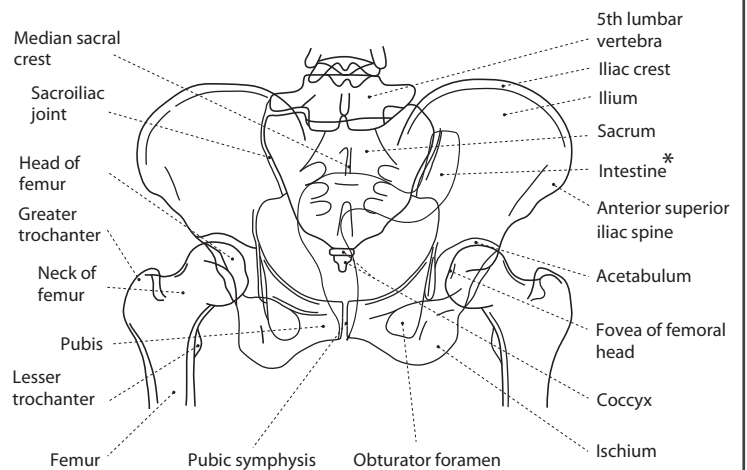
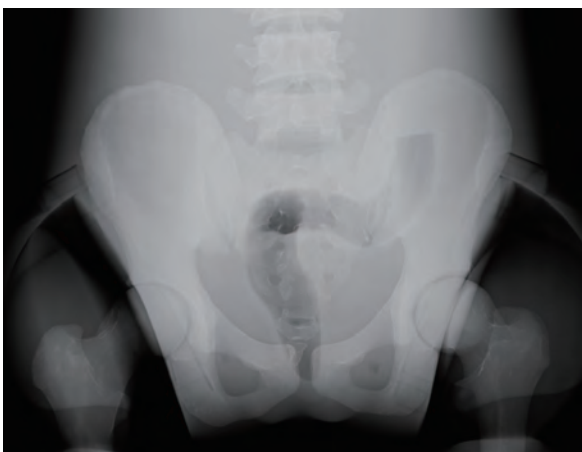● Point of X-ray Photography: Positioning and Direction of X-ray Radiation



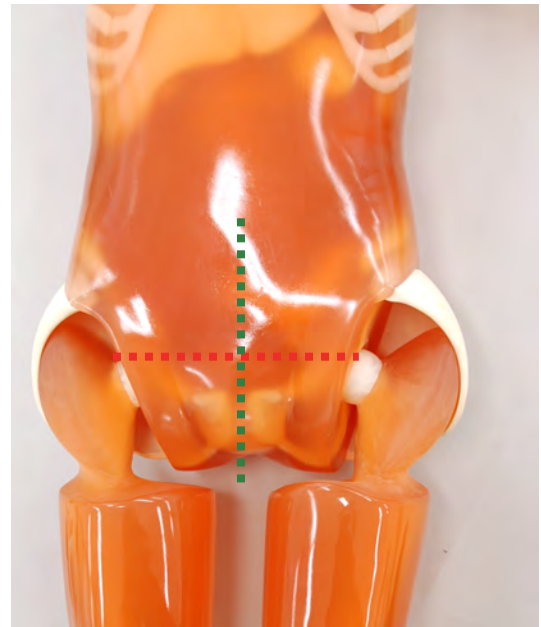
| ● Positioning | ● Direction of X-ray Radiation | ● Part of phantom used for this photography |
|-----------------|--|---|
| Supine position | Align the center to the midpoint of the line connecting the anterior superior iliac spine and the superior end of the pubic symphysis. Radiate X-ray along median plane. | trunk • thigh |

● Xray image and the name of bone

* Not represented when using PBU-50.



● Point of X-ray Photography: Positioning and Direction of X-ray Radiation



● Positioning

Supine position (bring both the big toes nearer to each other as possible.)

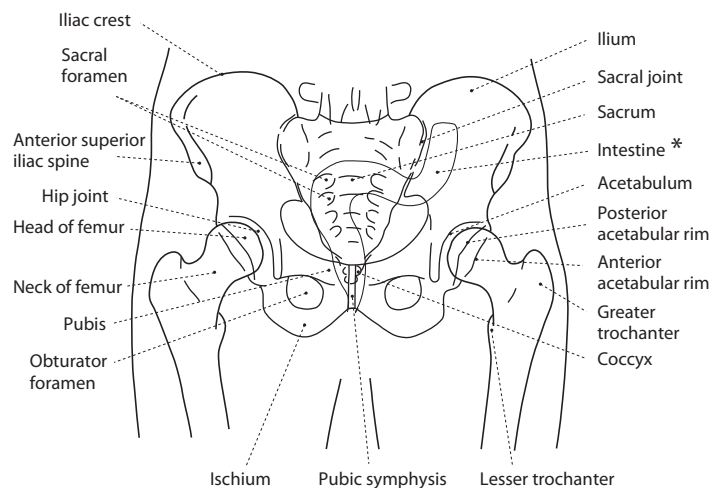
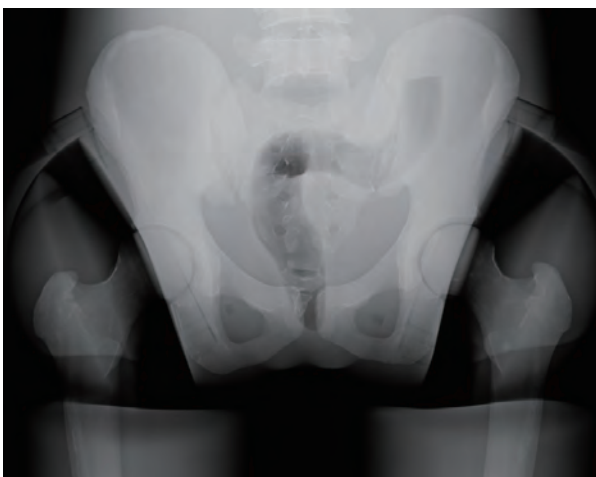● Direction of X-ray Radiation

Align the center to the point at 1/3 from the pubis side on the line connecting the anterior superior iliac spine and the superior end of the pubic symphysis. Radiate X-ray along median plane.

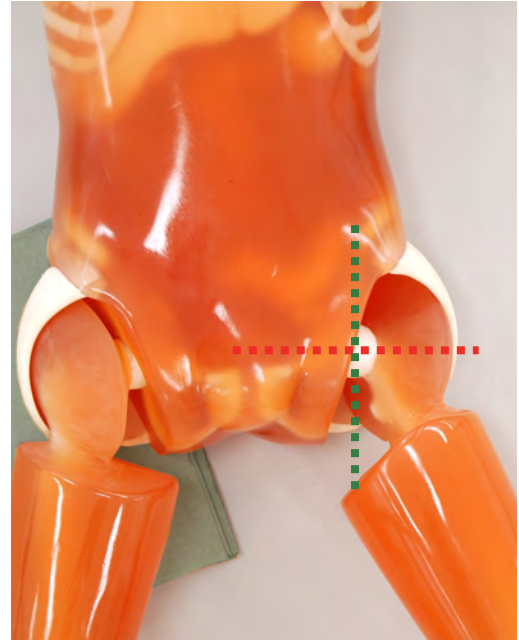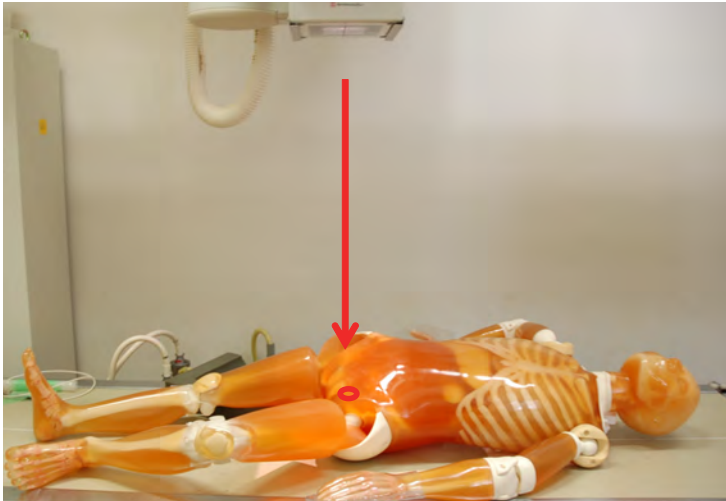
● Part of phantom used for this photography

trunk • thigh

● Xray image and the name of bone

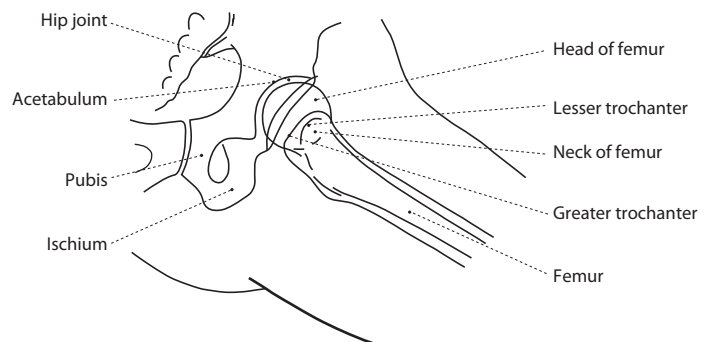
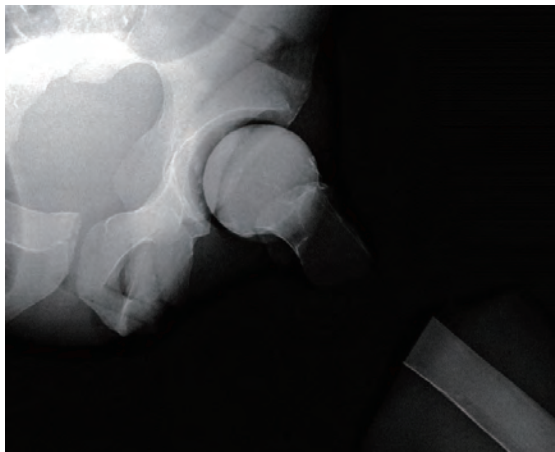


● Point of X-ray Photography: Positioning and Direction of X-ray Radiation

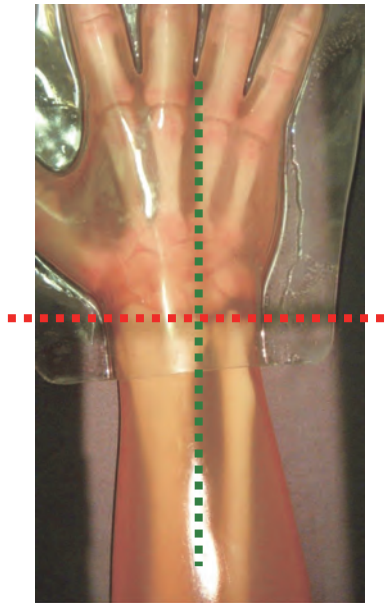



| ● Positioning | ● Direction of X-ray Radiation | ● Part of phantom used for this photography |
|---|--|---|
| Lift the side of the joint that is not targeted from the film to a 45 degree oblique position from the supine position. Flex the hip and knee joints. | Align the center to the point that is approximately the width of three fingers away from the midpoint of the line connecting the anterior superior iliac spine and the superior end of the pubic symphysis on the targeted side. Radiate X-ray to the center in the perpendicular direction. | trunk • thigh |

● Xray image and the name of bone

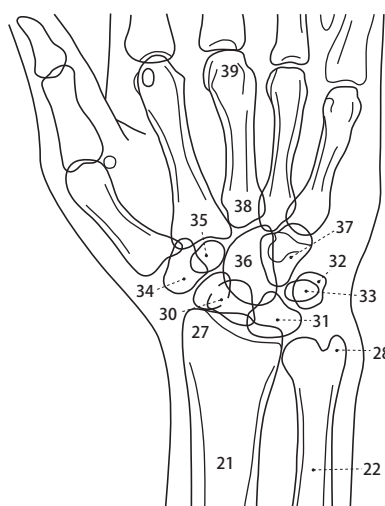
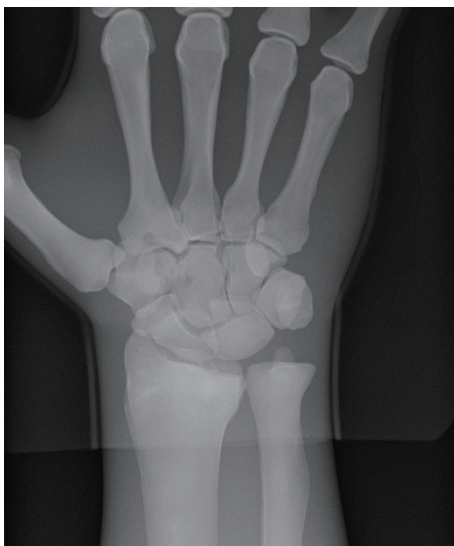

● Point of X-ray Photography: Positioning and Direction of X-ray Radiation




| ● Positioning | ● Direction of X-ray Radiation | ● Part of phantom used for this photography |
|---------------------|---|---|
| Turn the palm down. | Align the center to the midpoint of the line connecting the styloid processes of the ulna and the radius. Radiate X-ray to the center in the perpendicular direction. | forearm-hand |

● Xray image and the name of bone



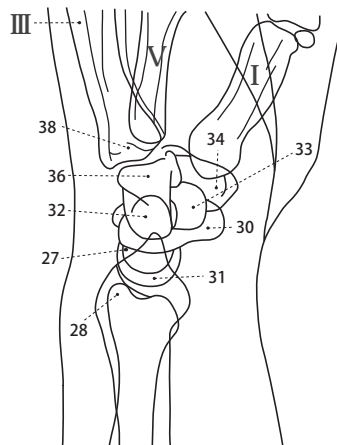
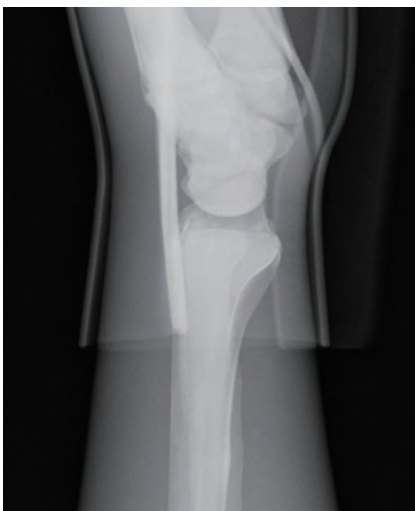- 21. Radius
- 22. Ulna
- 27. Styloid process of radius
- 28. Styloid process of ulna
- 29. Lunate articular surface of radius
- 30. Scaphoid
- 31. Lunate
- 32. Triquetrum
- 33. Pisiform
- 34. Trapezium
- 35. Trapezoid
- 36. Capitate
- 37. Hamate
- 38. Bases of metacarpal
- 39. Heads of metacarpal

● Point of X-ray Photography: Positioning and Direction of X-ray Radiation



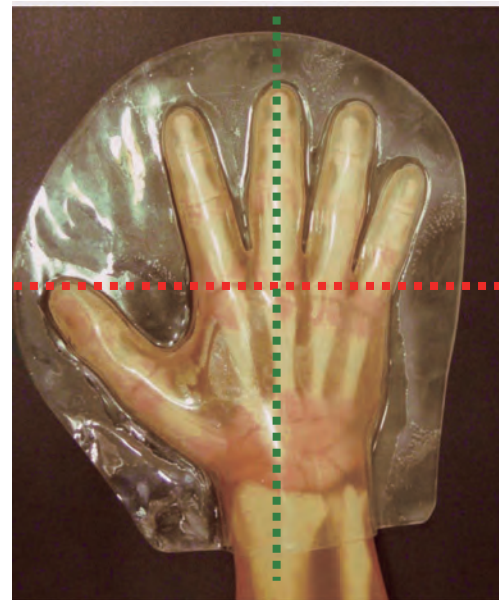

| ● Positioning | ● Direction of X-ray Radiation | ● Part of phantom used for this photography |
|---|--|---|
| Place the hand with the thumb facing upwards. | Align the center to the styloid process of radius. Radiate X-ray to the center in the perpendicular direction. | forearm-hand |

● Xray image and the name of bone



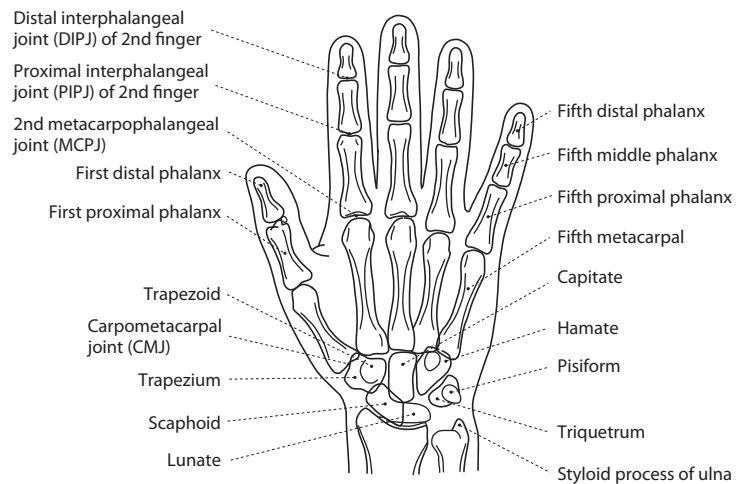
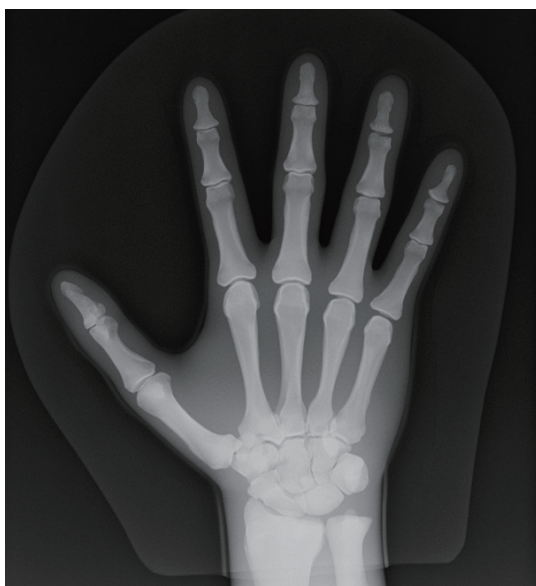- 27. Styloid process of radius
- 28. Styloid process of ulna
- 30. Scaphoid
- 31. Lunate
- 32. Triquetrum
- 33. Pisiform
- 34. Trapezium
- 36. Capitate
- 38. Bases of metacarpal

● Point of X-ray Photography: Positioning and Direction of X-ray Radiation

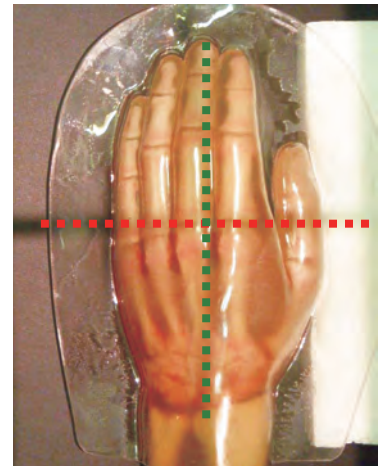

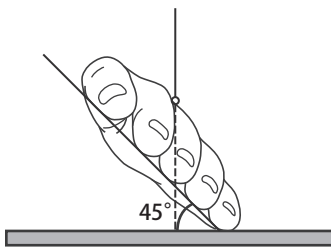


| ● Positioning | ● Direction of X-ray Radiation | ● Part of phantom used for this photography |
|---------------------|--|---|
| Turn the palm down. | Align the center to the 3rd metacarpophalangeal (MCP) joint. Radiate X-ray to the center in the perpendicular direction. | forearm-hand |

● Xray image and the name of bone



● Point of X-ray Photography: Positioning and Direction of X-ray Radiation



● Positioning

Adjust the angle by inserting assistance tool (The phantom restricts the angle to 30 degrees instead of 45 degrees.)

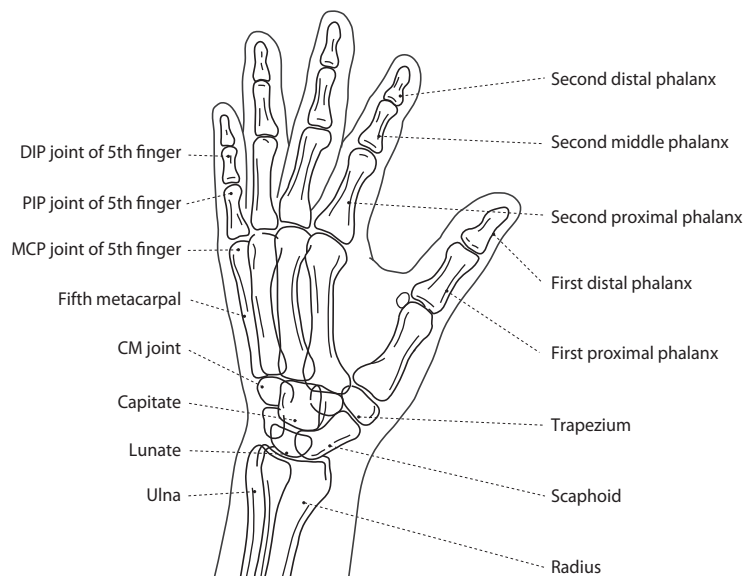
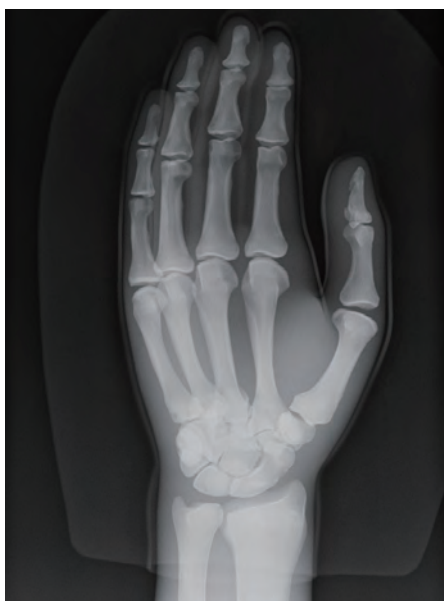● Direction of X-ray Radiation

Align the center to the 3rd metacarpophalangeal (MCP) joint. Radiate X-ray in the perpendicular direction to the center. (In the case of the inclination of 30 degrees)




● Part of phantom used for this photography

forearm-hand

● Xray image and the name of bone



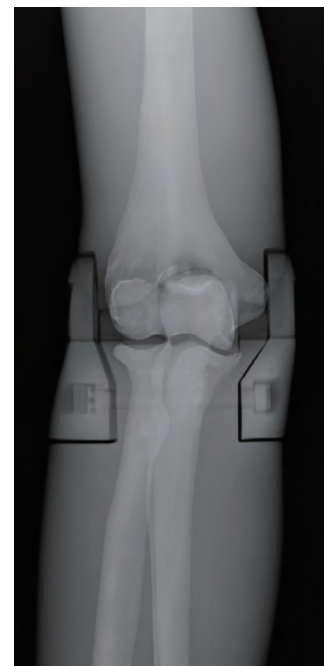

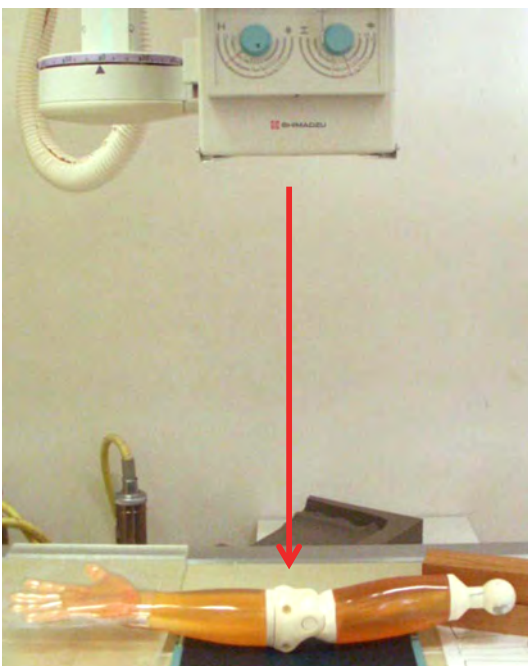
● Frontal projection of forearm



Turn the palm up (right hand)

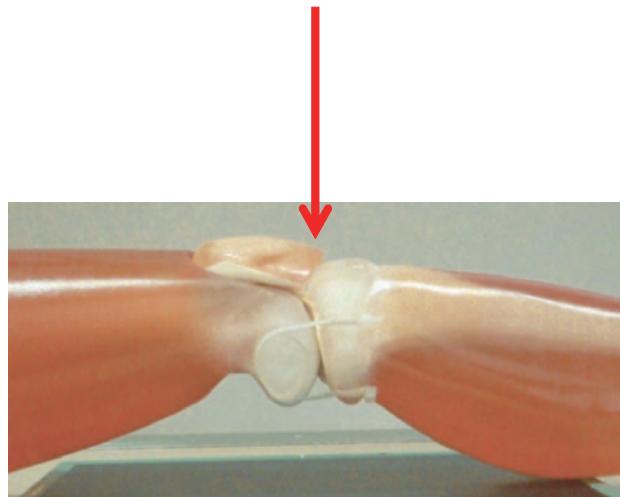

Radius and ulna are represented distinguishably.

● Frontal projection of elbow joint



Turn the palm up and extend the elbow.

● Point of X-ray Photography: Positioning and Direction of X-ray Radiation



● Positioning

Supine position
(Place the phantom as the patella is directed to the top.)

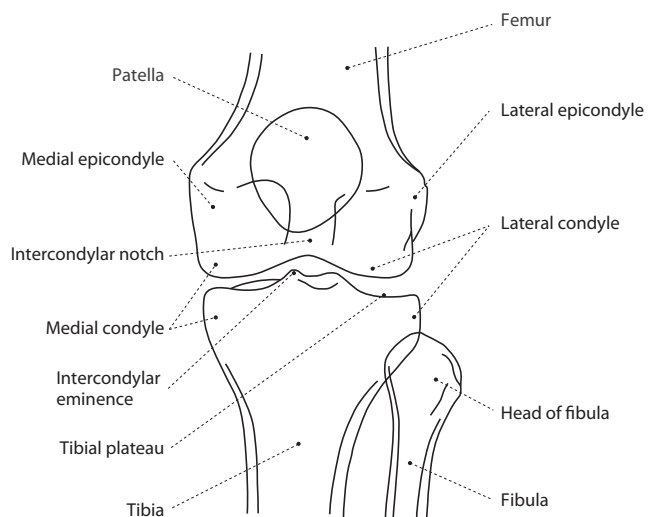
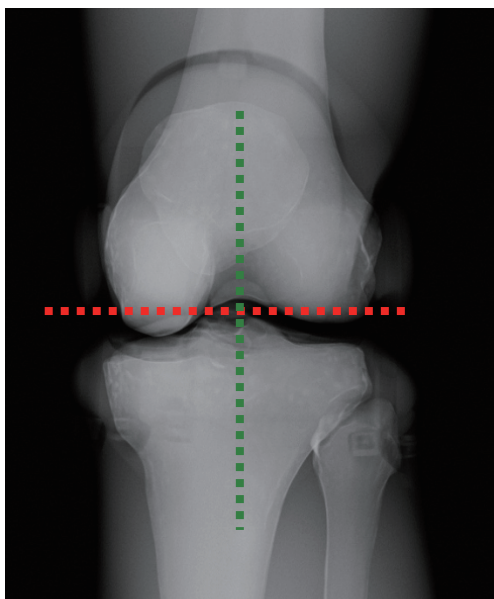
● Direction of X-ray Radiation

Align the center to the lower edge of the patella. Radiate X-ray to the center in the perpendicular direction.

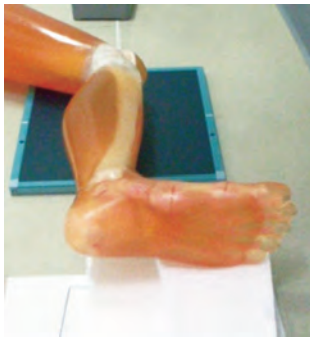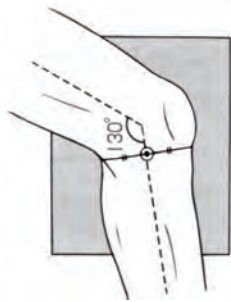
● Part of phantom used for this photography

Thigh • lower thigh-foot


● Xray image and the name of bone



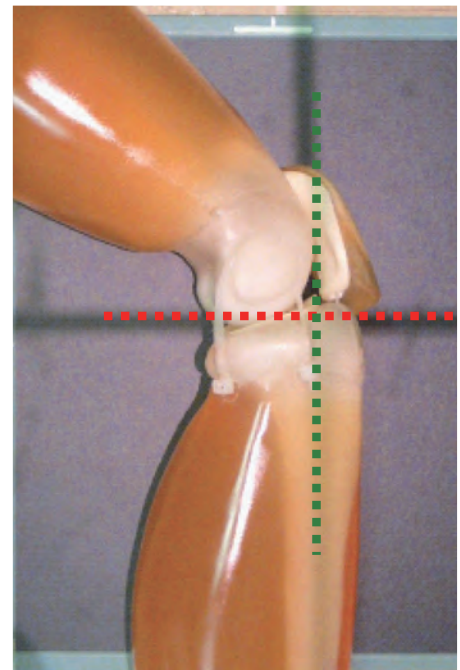
● Point of X-ray Photography: Positioning and Direction of X-ray Radiation



Place the phantom on the bed with the small toe facing down with the patella directed to the side and the heel suspended.



Insert tool to assist alignment of the heights of the thigh and the foot.



● Positioning

Decubitus position
(Direct the knee joint to the side and flex it to approximately 130 degrees.)

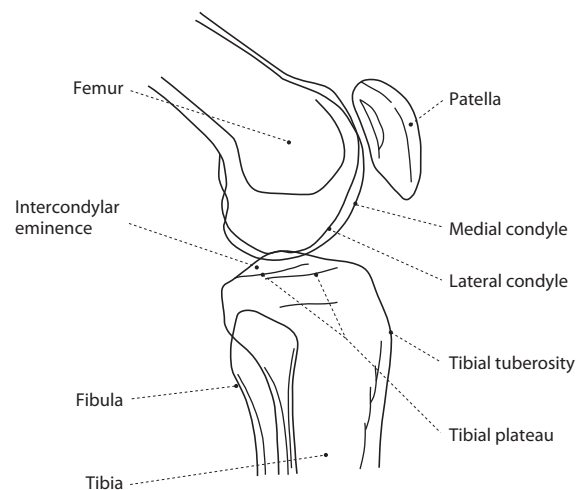
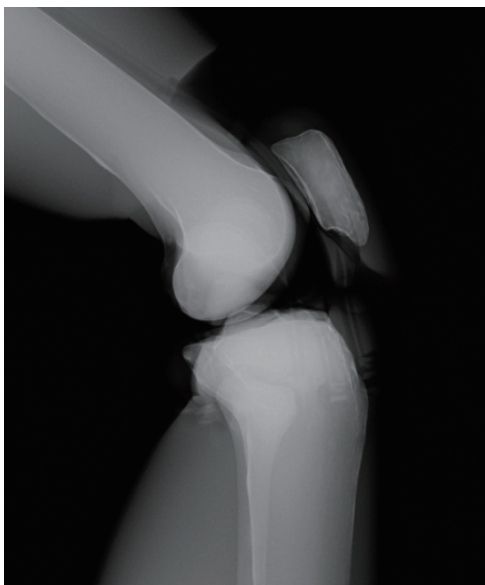
● Direction of X-ray Radiation

Align the center at a position slightly shifted to the back from the lower edge of the patella. Radiate X-ray to the center in the perpendicular direction.

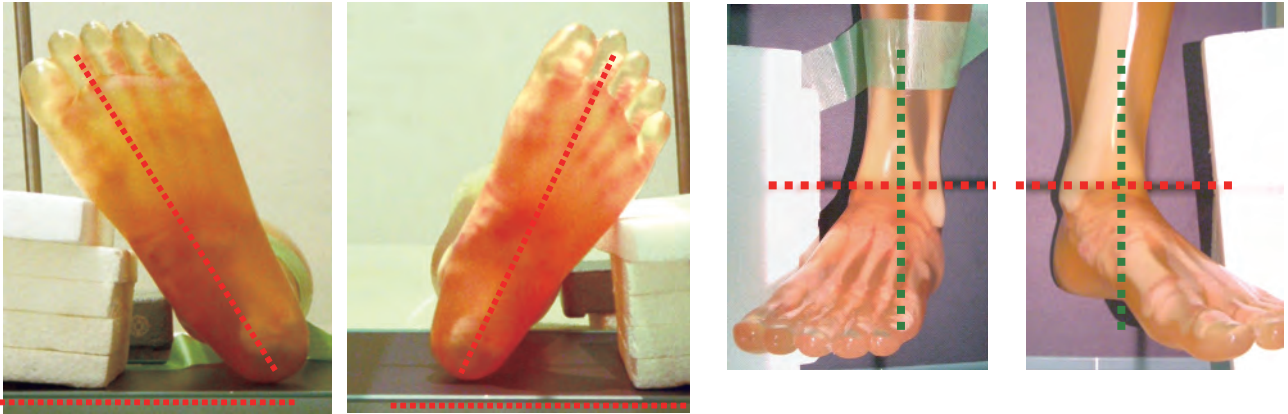
● Part of phantom used for this photography

Thigh • lower thigh-foot

● Xray image and the name of bone



● Point of X-ray Photography: Positioning and Direction of X-ray Radiation



● Positioning

Supine position
(Tilt the line connecting the second toe and the heel 20 - 30 degrees from the perpendicular position.)

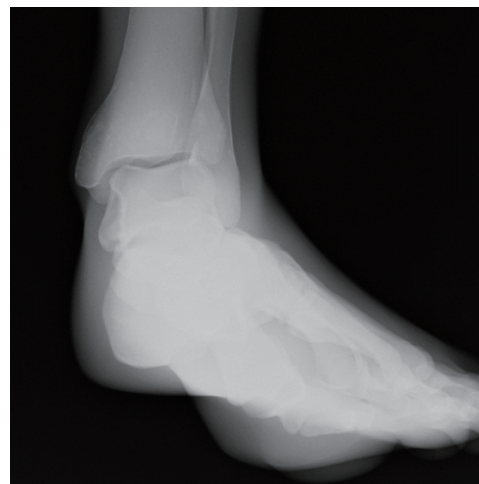
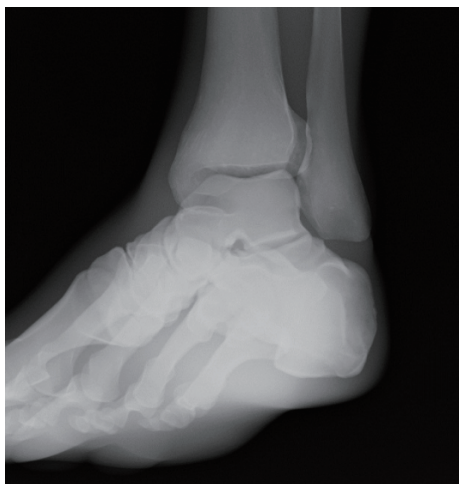
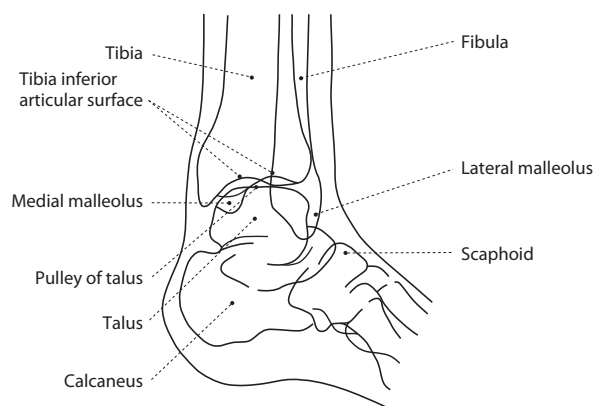
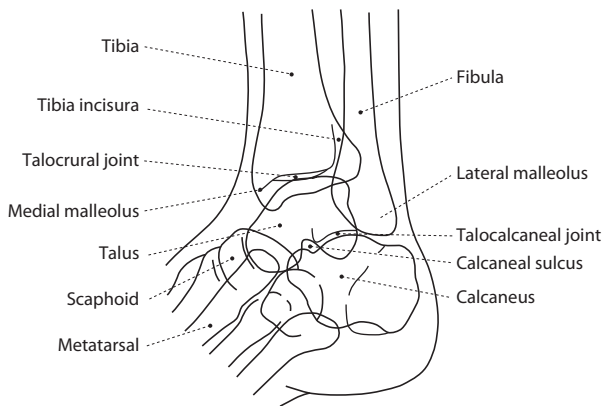
● Direction of X-ray Radiation

Align the center to the midpoint of the line connecting the medial malleolus and the lateral malleolus. Radiate X-ray to the center in the perpendicular direction.

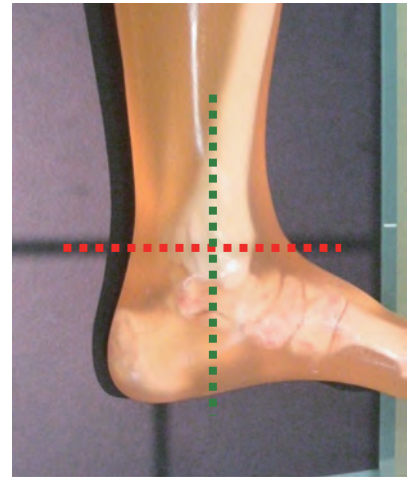
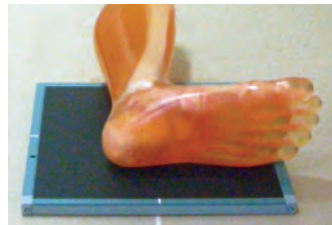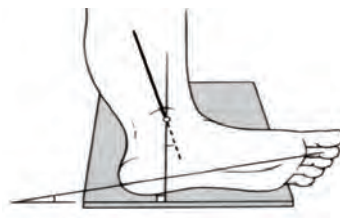

● Part of phantom used for this photography

lower thigh - foot

● Xray image and the name of bone



● Point of X-ray Photography: Positioning and Direction of X-ray Radiation



● Positioning

Decubitus position
(Attach the outer side of the foot to the film side and direct the second toe to 10 degrees from the film plane.)

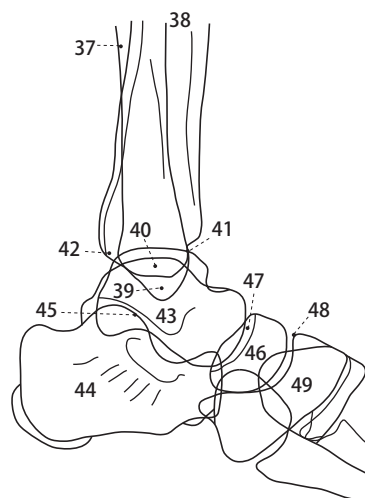
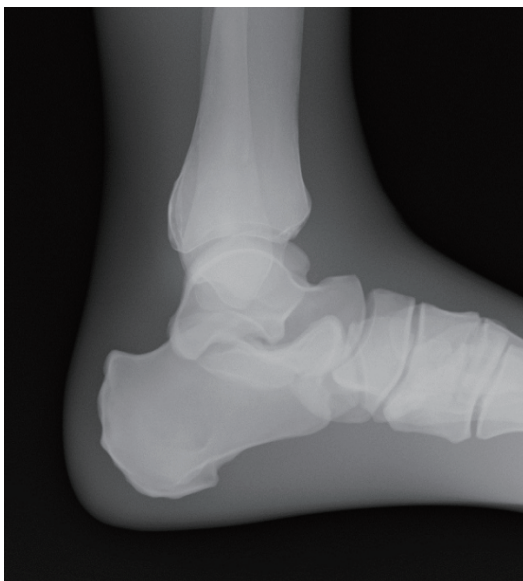● Direction of X-ray Radiation

Align the center to the medial malleolus.
Radiate X-ray to the center in the perpendicular direction.

● Part of phantom used for this photography

lower thigh - foot

● Xray image and the name of bone



Foot joint - lateral position

- 37. Fibula
- 38. Tibia
- 39. Lateral malleolus
- 40. Medial malleolus
- 41. Anterior margin of joint
- 42. Posterior margin of joint
- 43. Talus
- 44. Calcaneus
- 45. Talocalcaneal joint
- 46. Scaphoid
- 47. Talonavicular joint
- 48. Cuneonavicular joint
- 49. Cuneiform



Caution

Don't mark on the phantom with pen or leave printed materials contacted on its surface. Ink marks on the phantom will be irremovable.

Please contact manufacturer with any discrepancies in this manual or product feedback. Your cooperation is greatly appreciated.

KYOTO KAGAKU co.,LTD

<http://www.kyotokagaku.com> e-mail: rw-kyoto@kyotokagaku.co.jp

■ Main Office and Factory

15 KitaneKoya-cho Fushimi-ku Kyoto 612-8388, Japan
Telephone : 81-75-605-2510
Facsimile : 81-75-605-2519

■ KyotoKagaku America Inc.

USA,Canada,and South America
3109 Lomita Boulevard, Torrance, CA 90505 ,USA
Telephone : 1-310-325-8860
Facsimile : 1-310-325-8867