

M44 Visual-Tactile Breast Examination Simulator

Instruction Manual



M44 Visual-Tactile Breast Examination Simulator

This simulator provides training in Visual-Tactile Breast Examination skills. Four typical breast lumps can be differentiated by palpation.

The simulator is designed for medical education. Do not use for improper purpose.

Please read the instruction carefully before use.

Features:

1. Four typical breast lumps are palpable.
2. Examination skills for a case with skin dimple can be practiced.
3. Collarbone and ribs are palpable.

Set includes

Life size left breast model --- 1

Talcum powder --- 1

Size: W 200 x D 280 x H150 mm

DOs and DO'Ts

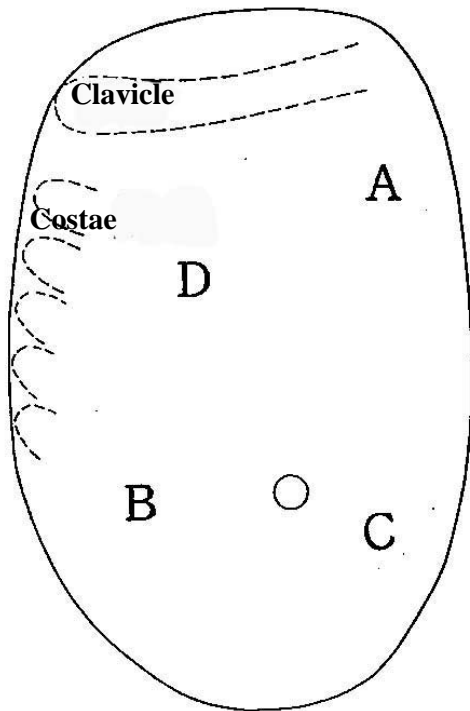
Do's

- 1) Handle the model with utmost care at all times. Model skin is special composition of soft resins.
- 2) Put talcum powder on the model skin before and after sessions. Add some powder while training sessions when the skin surface gets sticky.
- 3) Clean the model by wiping soft cloth with water or soap water, dry naturally and put talcum powder before storage.
- 4) For storage, lay the model horizontally, so that the breast faces upward.
Do not leave the model it upright or up-side down for long time.
- 5) To take off the case lid, open it and slide it horizontally to the left.

Don't

- 1) Do not pinch, dig your nail to the model or touch it by sharp instruments or handle it by excessive force.
It may cause breakage in the skin, and replacement of the torn skin will be charged.
- 2) Do not try to detach the model from the case. The model is fixed.
- 3) Don't mark on the model with pen or leave any printed materials in contact with their surface.
Ink marks on the models won't be removable.
- 4) Never wipe the model with paint thinner or other organic solvent.

Cases Items



A) Cancer with a dimple sign.

B) Cancer with a depression in the skin

C) Fibroadenoma

D) Mastopathy

A) Cancer with a dimple sign.

A dimple sign can be observed by putting the thumb and index finger on the surface with narrow (approx. 3cm) gap, and bring the fingers closer to each other.

The lesion is hard, and its surface is uneven. The boundary of the lesion is unclear at some part.

B) Cancer with a depression in the skin

The lesion is hard, and its surface is uneven. The boundary of the lesion is unclear at some part.

C) Fibroadenoma

A spherical lesion with smooth surface. Movable. The boundary of the lesion is clear.

D) Mastopathy

A lesion with elasticity, smooth surface and unclear boundary.

KYOTO KAGAKU CONTACT & ORDERING INFORMATION

Inquiries & Ordering:

Telephone +81-75-605-2510

Facsimile: +81-75-605-2519

URL: <http://www.kyotokagaku.com/>

Email: rw-kyoto@kyotokagaku.co.jp

Head Office:

Kyoto Kagaku Co. Ltd.
15 Kitanechoya-cho, Fushimi-ku
Kyoto, Japan 612-8388

USA & North America:

Kyotokagaku Co., Ltd. Los Angeles
3109 Lomita Boulevard. Torrance, CA 90505
Telephone +1-310-217-8083
Facsimile +1-310-217-9027

MEM Training Centre:

Kyotokagaku Co., Ltd. Tokyo Branch
5-20-4 Koishikawa Bunkyo-ku Tokyo, Japan 112-0002