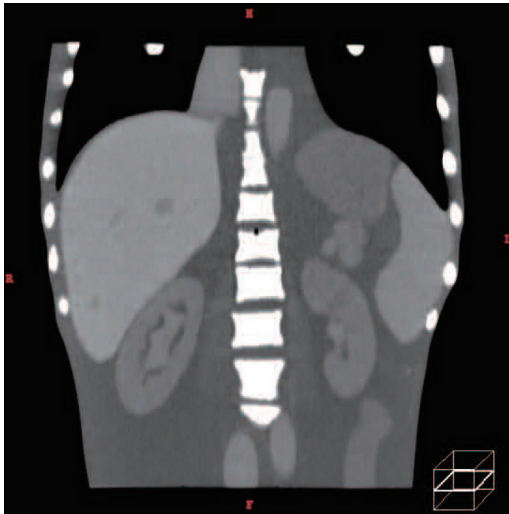
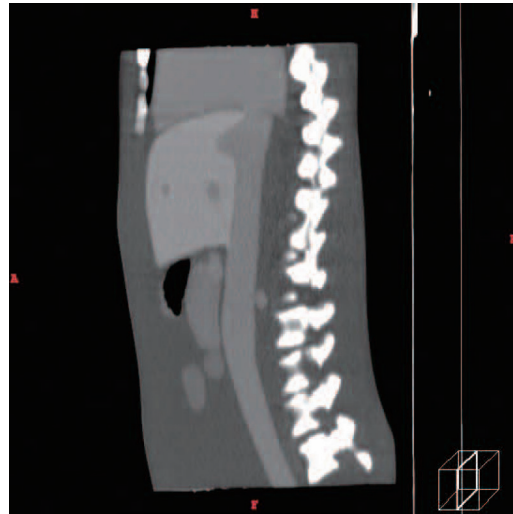


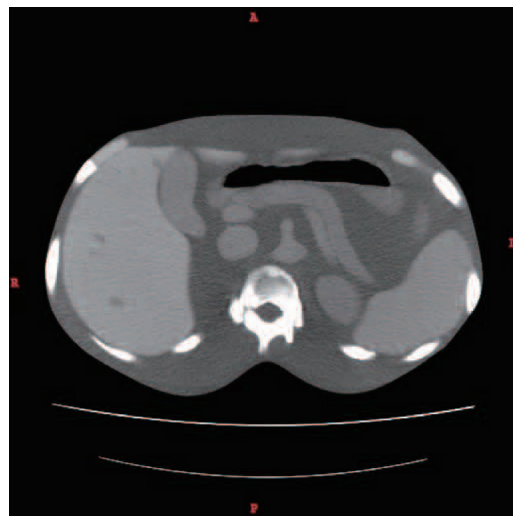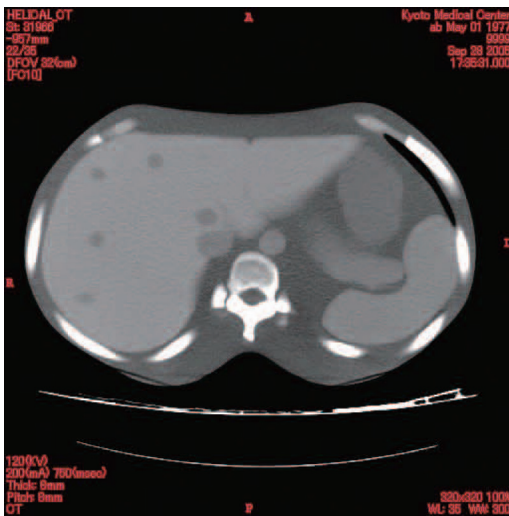
# PH-5 CT Abdomen Phantom



coronal



sagittal



axial